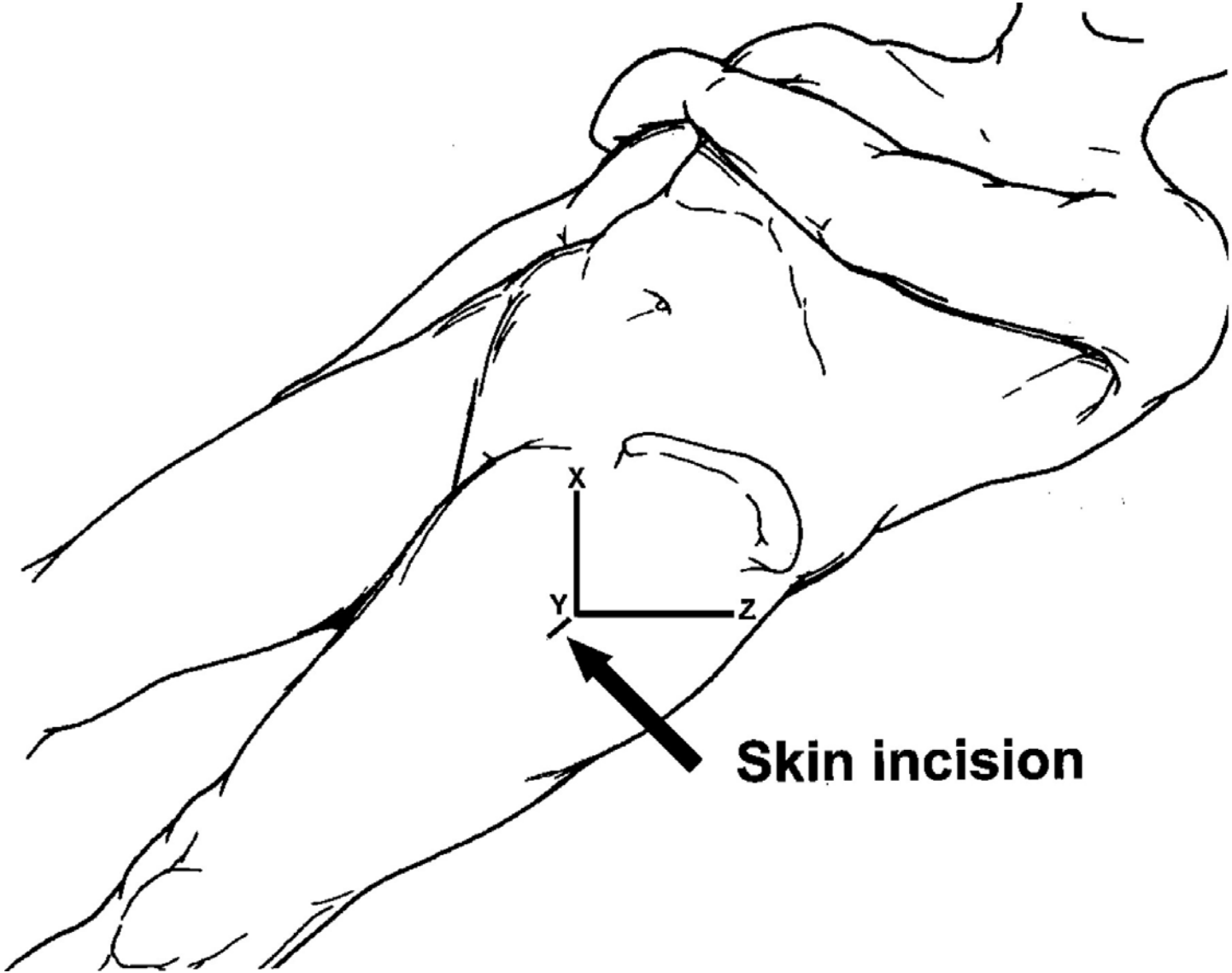


Fig. 4: Drawing showing the technique used for positioning the skin incision



Loder R. T. et.al. J Bone Joint Surg 2000:82:1170-1170